

21 November 2024

Matamata Veterinary
Services Ltd
362 Hinuera Road West
RD2, Matamata 3472
New Zealand
Tel 07 888 8193

SURGICAL REPORT

Re: Major Spirit – Downbytheseaside 2023
Microchip: 985100012202010
Owner: Woodlands Stud

On 21 November 2024 the above described filly underwent arthroscopic surgery of the left hock. A routine dorsal approach was made to the joint. Several small osteochondral fragments were present on the lateral aspect of the distal trochlear ridge of the tibia. These were removed and underlying bone was debrided to healthy margins. The joint was flushed and portals were closed routinely.

Management:

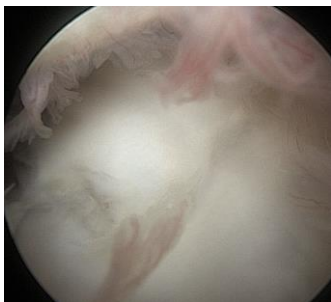1. Rest: please maintain the horse on box rest for two weeks followed by four weeks in a small yard.
2. Bute: give 8ml by mouth once a day for three days starting 23 November 2024.
3. Suture removal: please have sutures removed 2 December 2024.
4. Bandaging: please have the bandage changed in 24 hours and then every four days for three more bandage changes.
5. We recommend the use of Pentosan in the muscle and 4-Cyte in feed to encourage growth of healthy new cartilage in the three months following surgery. It is recommended to start this at suture removal.

Intravenous and intramuscular injections have been administered to this horse. Please monitor the catheter, injection sites, and incisions closely. Please contact the MVS Equine Hospital if there are any signs of heat, pain, swelling and/or discharge.

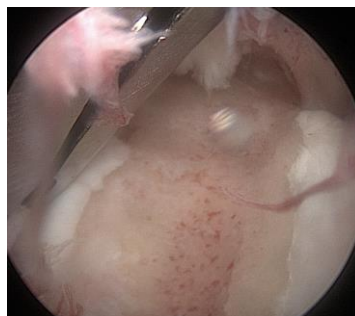
Yours sincerely



Barbara Hunter DVM MS MANZCVS DACVS-LA
Registered Specialist in Equine Surgery



Osteochondral lesion L Hock



Post-Debridement

Please ensure that this report is forwarded to the horse's owner(s) and the person(s) responsible for the future care of the horse, as well as to the insurer, if applicable.